



Versatility of a Superpulsed Diode Laser in Oral Surgery: A Clinical Report

Carlo Maiorana^a, Sergio Salina^b

^a Professor and Chair, Oral Surgery and Implantology, Dental Clinic ICP, University of Milano, Milano, Italy.

^b Attending Doctor, Oral Surgery and Implantology, Dental Clinic ICP, University of Milano, Milano, Italy.

Purpose: A superpulsed diode laser (Claros; Elexxion) was used for different surgical procedures using various operative parameters. The possibility of reaching the target tissue with lower power than and equivalent efficacy of the conventional diode laser was clinically tested.

Materials and Methods: After setting local anaesthesia (Ecoicain 1:100000), the superpulsed diode laser was used on patients to uncover impacted teeth, remove epulis, and treat intraoral hemangioma. No antibiotics were administered and chlorhexidine rinses were prescribed for one week, twice a day, before surgery.

Results: In all cases, slight carbonization was observed. The postoperative healing ensued without inflammation or complications.

Conclusion: The use of a superpulsed diode laser allows the surgeon to operate using high energy and very short pulse duration (milliseconds). This allows the best control of incision depth and reduces the thermal damage to the target tissue.

Keywords: superpulsed laser, oral surgery.

J Oral Laser Applications 2006; 6: 193-199.

The use of diode laser in oral surgery is becoming very popular for several procedures that can be performed quickly, with low morbidity and excellent healing due to the biostimulating effect of this specific laser. As we know, the active medium is a solid-state semiconductor that uses a combination of gallium, aluminum, and arsenide to change electric energy into light energy. The available wavelengths place this laser in the invisible nonionizing infrared radiation portion of the electromagnetic spectrum. These wavelengths are very well absorbed by pigmented tissues, such as hemoglobin and melanin. This tendency to transmit depends on the wavelength and the absorption factor of the target tissue.¹⁻³ The poor absorption in the surrounding tissues (only 20% of the emitted energy penetrates deeper than 2 mm) allows the surgery to be

performed safely.^{4,5} Surgery is usually performed in continuous mode, but the recently produced superpulsed diode laser allows the surgeon to perform interventions with very high energy levels (up to 20,000 Hz) with a pulse duration in the millisecond range. In this way, the thermal damage to the tissue does not progress deeper than 50 μm , and carbonization is reduced to a minimum.

MATERIALS AND METHODS

Three patients, men and women, in good general health, were selected for oral surgery. They presented with different pathologies: epulis, fornex hemangioma, and impacted teeth. A superpulsed diode laser (Clar-

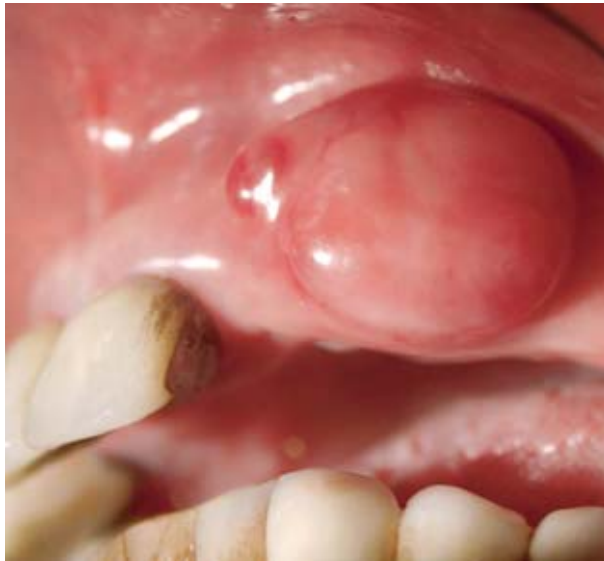

Fig 1 14-mm spheroidal epulis.

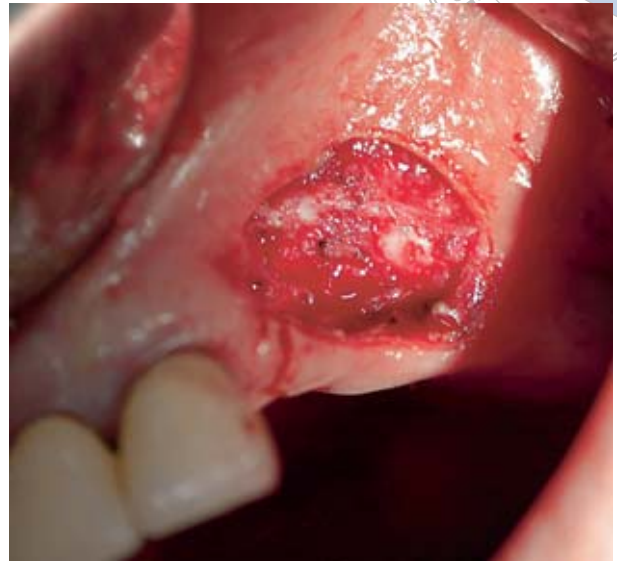

Fig 2 Immediate postoperative site.

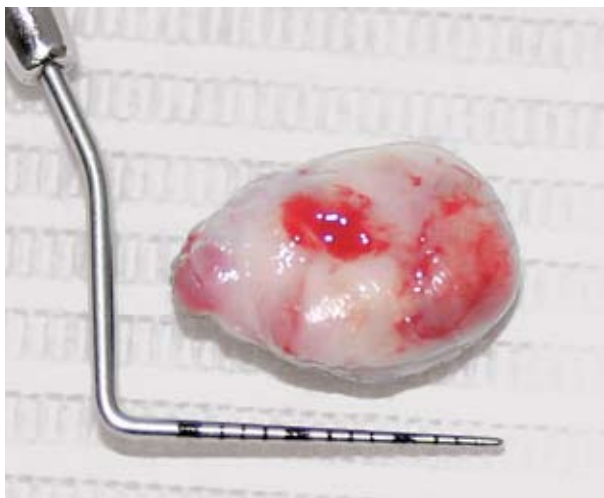


Fig 3 Epulis removed and sent for histological analysis.

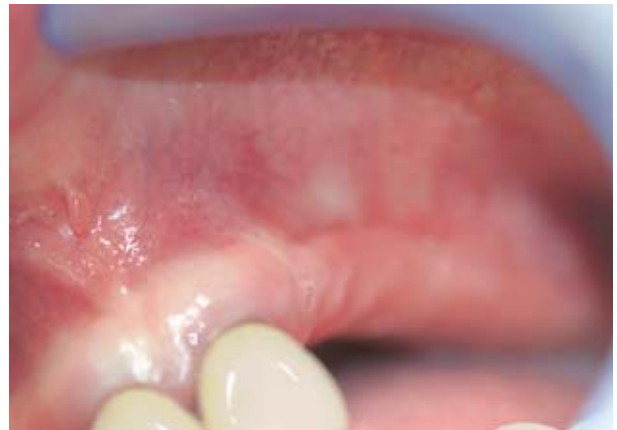

Fig 4 Surgical site 40 days postoperatively.

ion, Elexxion Medical Systems; Radolfzell, Germany) at 30 W and 20,000 Hz was used to excise the epulis and intraoral hemangioma, and uncover impacted the teeth.

CASE 1

This 62-year-old female patient had a large spheroidal durum epulis (14 mm) located on the gingival mucosa in dental area 23 (Fig 1). The most probable etiology

was chronic trauma produced by an ill-fitting removable prosthesis.

After giving local anesthesia (Ecocain 1:100000, Molteni Dental; Scandicci, Italy), the lesion was removed using superpulsed 809-nm diode laser set at 20 W and 20,000 Hz, with 10 μ s pulse duration (Fig 2). After removal, the epulis was sent in for the usual histological analysis (Fig 3).

The patient's removable prosthesis was immediately modified and relined with a soft tissue conditioner (Soft Liner, GC Europe NV; Leuven, Belgium). Chlor-

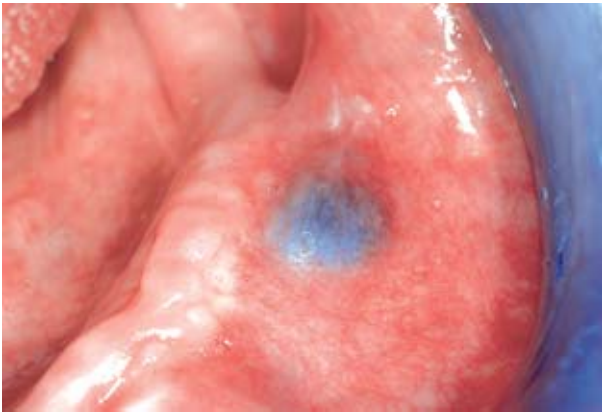


Fig 5 Intraoral 7-mm hemangioma.

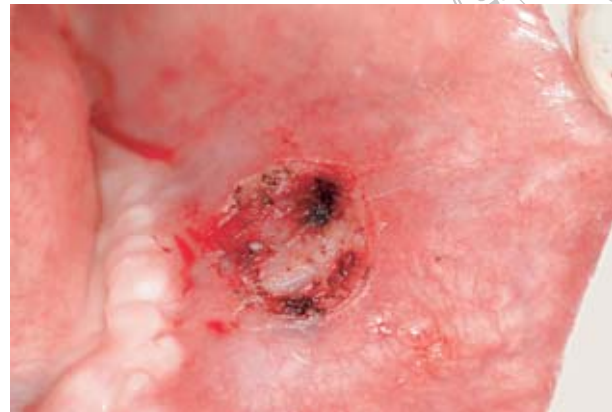

Fig 6 Immediate postoperative view with a thin, stable scar.

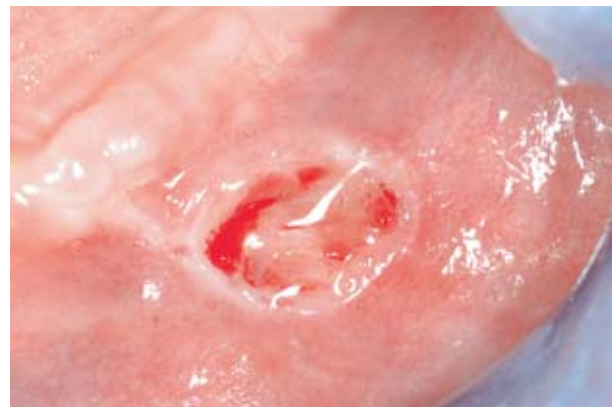


Fig 7 After 7 days: the postoperative site appears covered by newly formed tissue.

hexidine (0.2%) rinses were prescribed for one week, twice a day.

After 40 days, the treated area looked completely healed without shrinkage (Fig 4).

CASE 2

A round, 7-mm-wide hemangioma was observed on the inner side of the lower lip of a 75-year-old female (Fig 5). Because of the size and location, this lesion was removed in toto under local anesthesia, using a superpulsed diode laser. The laser parameters were: pulse output 25 W, pulse frequency 15,000 Hz, and pulse duration 10 μ s. This setting was enough to achieve the complete exeresis of the lesion and very effective coagulation with a stable scar (Fig 6). No sutures were necessary.

The patient was released without a prescription for antibiotics. Only chlorhexidine (0.2%) rinses for one week (twice a day) were suggested.

Healing proceeded rather quickly: just one week postoperatively, wound healing looked good (Fig 7): the epithelium defect due to the operation was already covered by newly formed tissue.

CASE 3

A 12-year-old male presented with both maxillary canines impacted. After a correct diagnosis and orthodontic preparation (bracket appliance for the maxilla) (Figs 8 to 12), the patient underwent a laser surgery session to uncover the buccally impacted teeth.

The superpulsed diode laser, set at 25 W and 15,000 Hz, with 10 μ s pulse duration, permitted inci-

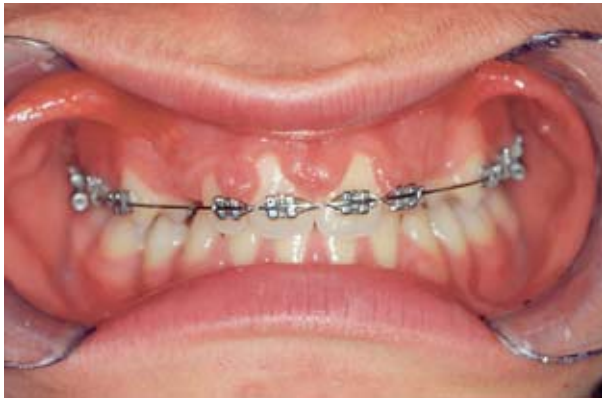

Fig 8 Maxillary orthodontic appliance: the two canines are not present.

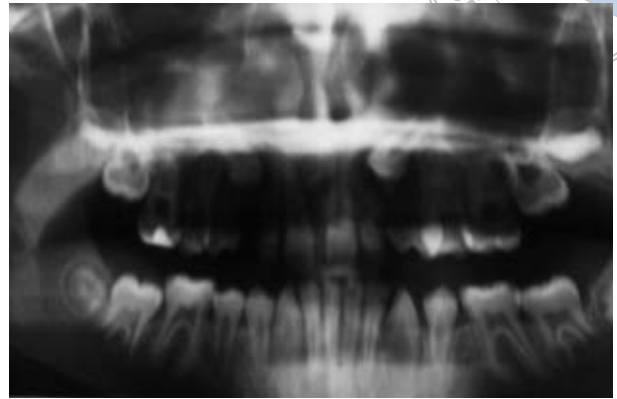


Fig 9 Panoramic radiograph: the two maxillary canines appears impacted.

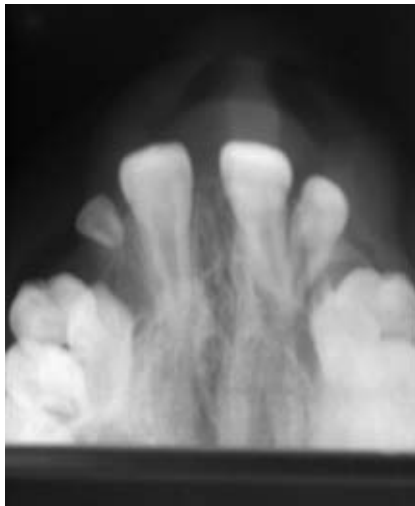

Fig 10 Occlusal radiographic image: the two maxillary canines appears buccally impacted.

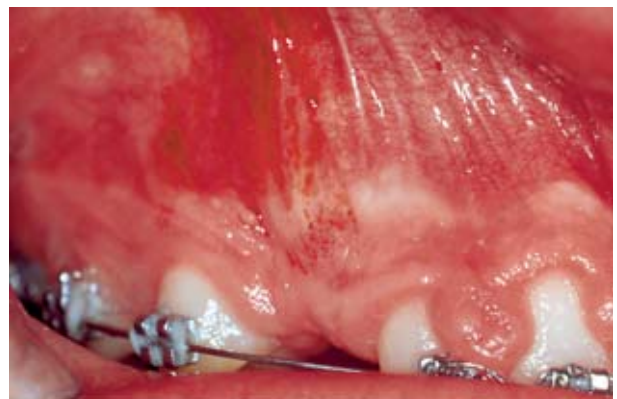


Fig 11 Canine area on the right side.

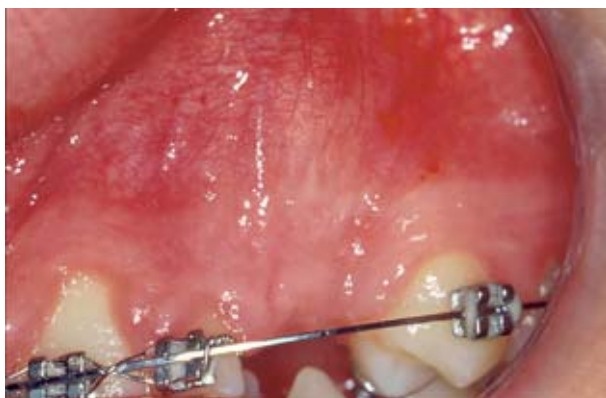

Fig 12 Canine area on the left side.

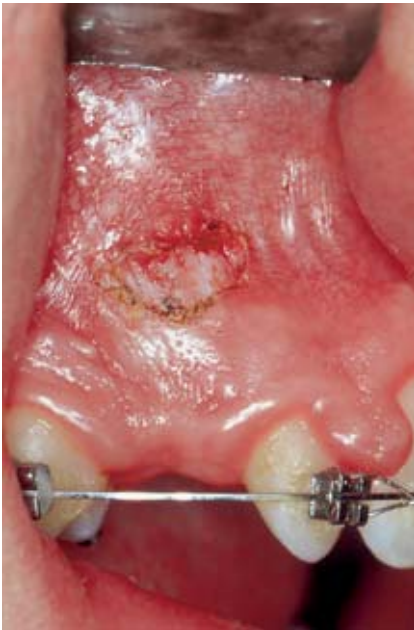

Fig 13 Canine area on the right side: first incision with super-pulsed diode laser.

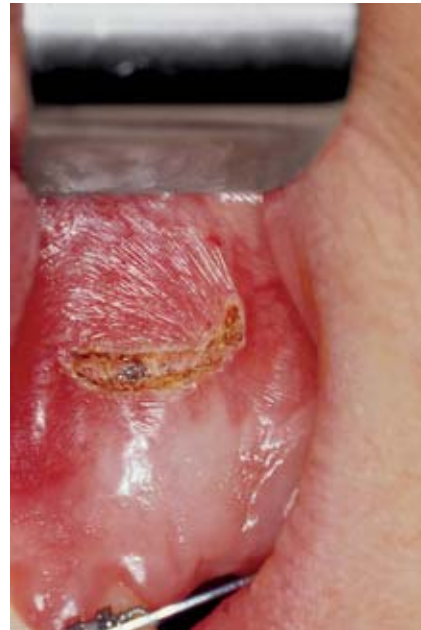

Fig 14 Canine area on the left side: first incision with super-pulsed diode laser.

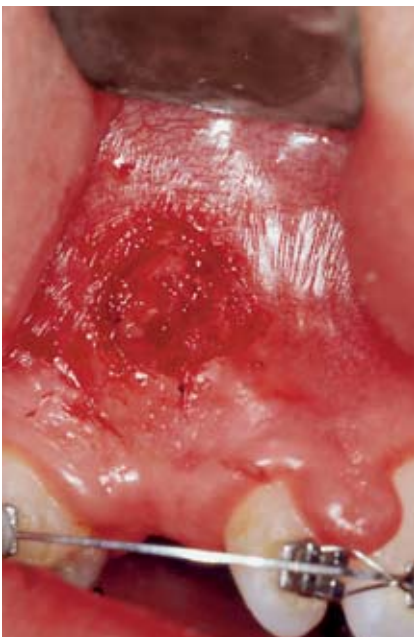

Fig 15 Uncovered right canine.

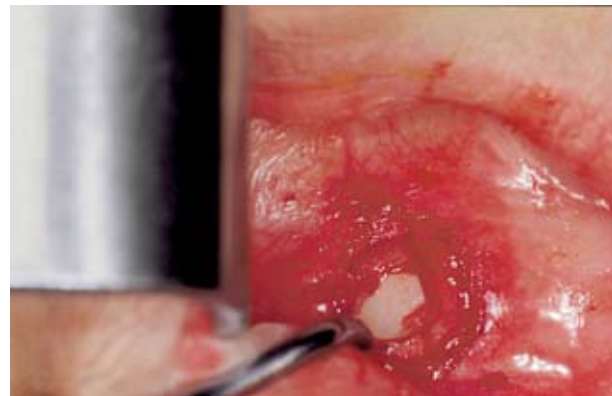


Fig 16 Uncovered left canine.

sion with immediately effective hemostasis (Figs 13 to 16), allowing establishment of a solid connection of the orthodontic brackets to the newly uncovered teeth (Figs 17 and 18).

The orthodontist joined the brackets to the arch, facilitating the correct eruption of the two canines. Four months later, the two teeth were completely erupted in the right position (Fig 19). A satisfactory amount of

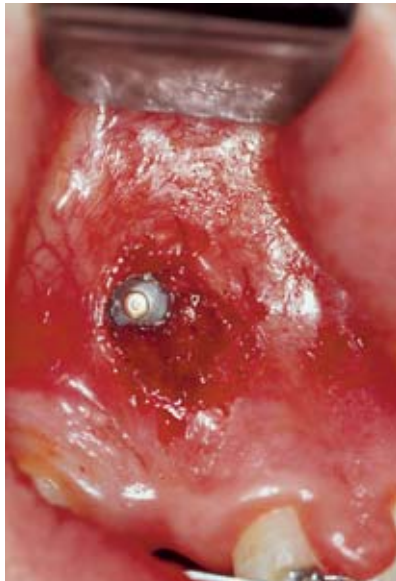

Fig 17 Orthodontic bracket linked to the right canine.

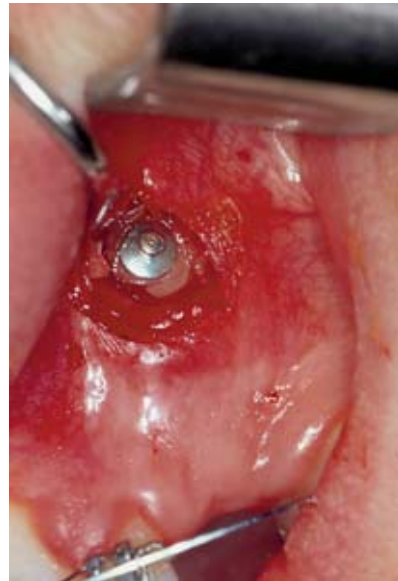

Fig 18 Orthodontic bracket linked to the left canine.

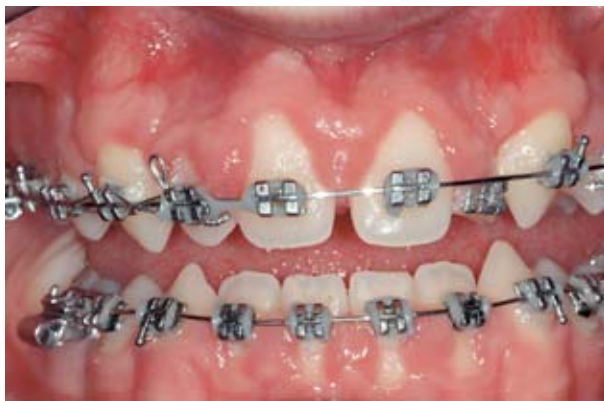

Fig 19 After 4 months: the two canines are in the correct position.

keratinized gingiva can be observed due to the suture of the follicular envelope to the oral epithelium, thus simulating the physiologic eruption process.

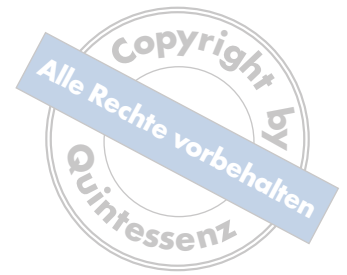RESULTS

All patients experienced a predictable and satisfactory healing process, without complications or side effects.^{6,7} No antibiotic prophylaxis was necessary, because laser surgery provided decontamination of the operating field⁸ and led to stable scar-tissue formation.^{9,10}

DISCUSSION AND CONCLUSION

The superpulsed 809 nm GaAlAs laser allows the excision of oral lesions of various consistency, such as epulides and hemangioma, with numerous advantages when compared to the conventional scalpel techniques:^{2,11,12}

- Clean cut without thermal side effects
- Instant coagulation of the surgical site
- Minimal involvement of the adjacent tissues during surgery
- Easy and safe to use
- Excellent postoperative conditions, minimal pain and swelling



- Reduced surgical stress for both the patients and the operator

Based on these results and the literature, this laser surgery can be considered the first choice for the excision of intraoral benign tumors, impacted teeth, or implant uncovering surgery, frenectomy, gingivectomy, and gingivoplasty.^{2, 9-12}

REFERENCES

1. Martelli FS, De Leo A, Zinno S. Laser in odontostomatologia: applicazioni cliniche. Milan: Masson Ed, 2000:59-60.
2. Maiorana C. Laser in the treatment of soft tissue lesions. *J Oral Laser Applic* 2003;2:7-14.
3. Moritz A. *Orale Lasertherapie*. Berlin: Quintessenz, 2005:41-45.
4. Goharkhay K, Moritz A. Effects on oral soft tissue produced by a diode laser in vitro. *Laser Surg Med* 1999;25:401-406.
5. Romanos G, Nentwig GH. Diode laser in oral and maxillofacial surgical procedures: clinical observations based on clinical applications. *J Clin Laser Med Surg* 1999;17:193-197.
6. Maiorana C, Salina S, Censi R et al. Nd:YAG laser in soft tissue surgery: a two-year retrospective study on 130 patients. *J Oral Laser Applic* 2001;1:29-34.
7. White JM, Chaudhry SI, Kudler JJ, et al. Nd:Yag and CO2 laser therapy of oral lesions. *J Clin Laser Med Surg* 1998;16:299-304.
8. Moritz A, Schoop U, Goharkhay, et al. Treatment of periodontal pockets with a diode laser. *Laser Surg Med* 1998;22:302-311.
9. Gold SI, Vilardi MA. Pulsed laser beam effects on gingival. *J Clin Periodont* 1994;21:391-396.
10. Salina S, Maiorana C, Censi R, et al. Treatment of oral fibromata using the Nd:YAG laser. *J Oral Laser Applic* 2001;1:59-64.
11. Pick RM. Using lasers in clinical dental practice. *J Am Dent Assoc* 1993;124:37-47.
12. Maiorana C, Salina S. *Laser a Diodi: applicazioni cliniche*. Milano: Ariesdue, 2004.

Contact address: Prof. Carlo Maiorana, Via Torino 51, 20123 Milano, Italy. Fax: +39-0280-51204. e-mail: carlo.maiorana@unimi.it